



Published in final edited form as:

*Am J Surg Pathol.* 2010 July ; 34(7): 965–969. doi:10.1097/PAS.0b013e3181dc5e8a.

## PAX8 (+)/p63 (–) Immunostaining Pattern in Renal Collecting Duct Carcinoma (CDC):

### A Useful Immunoprofile in the Differential Diagnosis of CDC Versus Urothelial Carcinoma of Upper Urinary Tract

Roula Albadine, MD<sup>\*</sup>, Luciana Schultz, MD<sup>\*</sup>, Peter Illei, MD<sup>\*</sup>, Dilek Ertoy, MD<sup>†</sup>, Jessica Hicks, MS<sup>\*</sup>, Rajni Sharma, PhD<sup>\*</sup>, Jonathan I. Epstein<sup>\*,‡,§</sup>, and George J. Netto, MD<sup>\*,‡,§</sup>

<sup>\*</sup>Department of Pathology, Johns Hopkins University, Baltimore, MD

<sup>‡</sup>Department of Urology, Johns Hopkins University, Baltimore, MD

<sup>§</sup>Department of Oncology, Johns Hopkins University, Baltimore, MD

<sup>†</sup>Department of Oncology, Hacettepe University, Ankara, Turkey

### Abstract

**Background**—Collecting duct carcinoma (CDC) is a relatively rare but aggressive type of renal malignancy with variable morphologic features. One of the World Health Organization diagnostic criteria for CDC is the exclusion of urothelial carcinoma of renal pelvis from the differential diagnosis. PAX8 is a novel lineage restricted transcription factor expressed in renal tubules. We investigated the expression pattern of PAX8 in CDC and its utility, in combination with p63, in resolving the differential diagnosis of CDC versus upper tract urothelial carcinoma (UUC).

**Design**—Archival tissues from 21 CDC and 34 UUC were retrieved from our institutional files. Immunohistochemistry for PAX8 and p63 were performed on routine and tissue microarray sections using standard immunohistochemistry protocol. Intensity of nuclear staining was evaluated for each marker and assigned an incremental 0, 1+, 2+, and 3+ score. Extent of staining was categorized as focal (<25%), nonfocal (25% to 75%), or diffuse (>75%).

**Results**—CDC: All 21 (100%) CDC were positive for PAX8. Intensity of expression was moderate to strong (2+/3+) in 19 cases (90%). Extent of staining was diffuse in 13 of 21 tumors. The p63 was positive in 3 of 21 (14%) CDC cases (PAX8+/p63+). UUC: The 34 UUC included 5 pT1, 4 pT2, and 25 pT3/pT4 tumors. Thirty-one of 34 (91.2%) UUC were negative for PAX8, whereas 33 of 34 (97%) were p63 positive. Staining intensity was moderate in 15 cases (44%), of which 12 were nonfocal or diffuse. The unique p63-negative UUC was a pT1 tumor that was also negative for PAX8 (PAX8–/p63–).

**Conclusions**—We propose the use of the combination of PAX8 and p63 in the diagnosis of poorly differentiated renal sinus epithelial neoplasms where the differential diagnosis includes CDC versus UUC. The immunoprofile of PAX8+/p63– supports the diagnosis of CDC with a sensitivity of 85.7% and a specificity of 100%. In contrast, a (PAX8–/p63+) profile supports the diagnosis of UUC with a sensitivity of 88.2% and a specificity of 100%. The inverse PAX8/p63 expression seen in CDC and UUC supports a renal tubular rather than an urothelial differentiation in CDC given the nephric lineage restriction of PAX8.

## Keywords

collecting duct carcinoma; urothelial carcinoma; PAX8; p63

Collecting duct carcinoma (CDC) is an aggressive subtype of the renal epithelial neoplasm that is thought to be derived from the collecting duct system. CDCs affect middle-aged adults with a mean age of 55 years (range: 13–83 y). Their male-to-female incidence ratio is 2:1. They are usually centered in the renal sinus region and present with advanced stage.<sup>12</sup>

The diagnosis of CDC is to some extent one of exclusion. A major diagnostic criterion, as indicated by Srigley et al,<sup>15</sup> is the exclusion of upper tract urothelial carcinoma (UUC). Distinguishing invasive pelvic UUC from CDC is of particular importance, given the differences in prognosis and treatment. Immunohistochemical markers such as high molecular weight cytokeratins (HMWCK) and *Ulex europaeus* lectin agglutinin have been used in this setting with only limited utility.<sup>5,8,9</sup>

PAX8 is a transcription factor of nephric, thyroid, and mullerian duct lineage specificity. Non-neoplastic renal tubules, including collecting ducts, have been shown to express PAX8<sup>13</sup> whereas lacking p63 expression,<sup>11</sup> a commonly used marker of urothelial differentiation. In this study, we examine the use of the combination of PAX8 and p63 in the differential diagnosis of CDC and UUC.

## MATERIALS AND METHODS

### Patient Cohort

Our study was approved by the institutional review board at Johns Hopkins Hospital. Electronic surgical pathology records were retrospectively searched for all cases with an original diagnosis of CDC in the period between 1989 and 2008. Twenty-seven cases were retrieved and reviewed by 2 senior uropathologists in the study (G.J.N. and J.I.E.) using the 2004 World Health Organization (WHO) criteria for CDC.<sup>3</sup> The diagnosis of CDC was confirmed in 21 cases representing the total number of CDCs included in this study. The remaining 6 cases were reclassified as low grade tubulo-cystic carcinoma, renal medullary carcinoma, and invasive high grade urothelial carcinoma (2 cases each). Routine formalin-fixed paraffin-embedded sections (FFPE) were used in 11 CDC cases, 9 of which were also represented in a tissue microarray set (TMA) containing a total of 19 CDCs.

In addition, 34 cases of invasive high-grade UUC were retrieved from our database (2005 to 2008) and reviewed for confirmation of their initial diagnosis. Twenty-five of the UUC cases with paired benign urothelium were used for the construction of a second TMA. Routine FFPE sections were used in the remaining 9 UUC cases. Staging and other pertinent clinicopathologic findings were assessed in all cases.

TMA construction was performed as described earlier using Beecher Instrument (Silver Spring, MD).<sup>4</sup> Each tumor was spotted 3 to 7 times in 1.6mm diameter cores.

### Immunohistochemistry Analysis

Immunohistochemical analysis for PAX8 and p63 was performed on 4  $\mu$ m TMA and routine FFPE sections using standard protocols as described below.

### PAX8

Immunostaining was performed using Bond max Leica autostainer (Leica Microsystems, Bannockburn, IL). Sections were deparaffinized, hydrated, and subjected to heat-induced

antigen retrieval for 20 minutes with high pH HIER (heat induced epitope retrieval). Rabbit polyclonal anti-PAX8 (Protein tech Group, Chicago, IL; 1:100 dilution) was applied for 15 minutes at room temperature followed by application of Biotin-free bond polymer refine detection. The 3-3'-diaminobenzidine chromogen was used to visualize the reaction (all reagents from Leica Microsystems, Bannockburn, IL) and then counterstained with hematoxylin.

## P63

Unstained sections were deparaffinized, rehydrated in graded alcohols, and subjected to heat-induced antigen retrieval for 20 minutes in citrate buffer using a steamer. Sections were then incubated for 45 minutes at 37°C with Ab-4 monoclonal mouse anti-p63 antibody (dilution 1:50; NeoMarkers, Fremont, CA). After the application of a secondary antibody, slides were developed for 20 minutes using 3-3'-diaminobenzidine chromogen and counterstained with hematoxylin.

Intensity of PAX8 and p63 nuclear staining was evaluated in each case and assigned an incremental 0, 1+, 2+, 3+ score. Extent of staining was categorized as focal (positive in less than 25% of the tumor cells), nonfocal (positive in 25% to 75% of cells), or diffuse (positive in more than 75% of cells).

## Statistical Analysis

The sensitivity and specificity of each marker as well as the diagnostic positive predictive values of their combination were subsequently determined in both types of tumors. Pairwise correlation coefficients (CC) were calculated to test relationship of p63 and PAX8 expression between TMA spots and routine whole-slide sections using the Stata 9.2 software package (StataCorp; college Station, TX).

## RESULTS

### Cohort Characteristics

**CDC**—The mean patient age at nephrectomy was 61 years (range: 33 to 82 y) and the mean tumor size was 6.5 cm (range: 2 to 12 cm). The male to female ratio was 2:5. All CDC tumors by definition were high grade. With the exception of one pT1 CDC, all tumors were pT3 stage. Four CDC tumors demonstrated focal tubulocystic architectural pattern and 2 contained areas consistent with colonization of pelvic urothelium. One CDC had areas suggestive of urothelial differentiation whereas 2 other tumors revealed foci of sarcomatoid carcinoma.

**UUC**—The mean patient age at nephrectomy was 70 years (range: 44 to 84 y) and the mean tumor size was 4.2 cm (range: 1.1 to 9 cm). The male to female ratio was 5:3. The 34 UUC tumors included 5 pT1, 4 pT2, and 25 pT3 or higher tumors. All UUCs were classified as invasive high-grade urothelial carcinoma according to the 2004 WHO/International Society of Urological Pathology classification. Eight tumors demonstrated focal, to occasionally extensive, extension into preexisting non-neoplastic collecting duct elements.

**Immunohistochemical Findings**—Immunohistochemical results are summarized in Table 1 and illustrated in Figure 1. The sensitivity and specificity of each antibody and their combination, along with the diagnostic positive predictive values are reported in Table 2.

**PAX8**—PAX8 expression was purely nuclear. All 21 (100%) CDC tumors were positive for PAX8 (Figs. 1A–C). The intensity of expression was moderate to strong (2+/3+) in 19 cases (90%). Extent of staining was diffuse (>75% of tumor cells) in 13 of 21 tumors, nonfocal in

7 of 21, and focal 3+ in 1 (4.8%). Diffuse PAX8 expression was observed in proximal and distal renal tubules in the paired benign renal tissue. PAX8 expression was accentuated in the distal renal tubules. Only 3 of 34 (8.8%) UUC tumors showed PAX8 reactivity, 2 focal, and 1 nonfocal in extent. The latter was limited to the noninvasive papillary component. PAX8 positivity was 100% sensitive, but 91.2% specific for CDC.

**P63**—Thirty-three of 34 (97%) UUC expressed p63 (Figs. 1D–F), 10 (29%) of the p63-positive UUCs showed diffuse expression with strong intensity. Staining intensity was moderate in 15 additional cases (44%) of which 3 were focal, 7 nonfocal, and 5 diffuse. The staining was absent in one case of microinvasive pT1 UUC. Only 3 of 21 CDC (14.3%) expressed p63. In the CDC lesion demonstrating morphologic evidence of urothelial differentiation, nonfocal moderate nuclear p63 staining was observed corresponding to the areas of urothelial differentiation. Nonfocal strong expression was also observed in areas of sarcomatoid transformation in one additional case. Eighteen of 21 (85.7%) CDC cases were negative for p63. P63 was 97% sensitive and 85.7% specific for UUC.

**Combination of PAX8 and p63**—With the exception of 3 tumors, all CDCs were PAX8 positive and p63 negative. Furthermore, the PAX8+/p63– profile was only encountered in CDCs giving this expression profile an 85.7% sensitivity, 100% specificity, and 100% diagnostic positive predictive value for CDC. Thirty of 34 UUC (88.2%) were PAX8 negative and p63 positive. The latter PAX8–/p63+ profile was only encountered in UUC cases (88.2% sensitivity, 100% specificity, and 100% positive predictive value). Looking at the entire cohort of renal sinus tumors (55 cases), 48 of 55 tumors had one of the above 2 profiles: PAX8+/p63– versus PAX8–/p63+. The nonconforming tumors included 3 CDC and 3 UUC that were positive for both markers (PAX8+/p63+) and 1 UUC that was negative for both markers.

**Correlation of Routine and TMA Section Expression**—In the subset of CDC cases that had both TMA and routine FFPE representation, strong correlation of expression patterns of both PAX8 (intensity  $CC=0.97$ ,  $P=0.000$ ; extent  $CC=0.75$ ,  $P=0.019$ ) and p63 (intensity  $CC=0.50$ ,  $P=0.17$ ; extent  $CC=0.75$ ,  $P=0.019$ ) were documented between the 2 methods of sampling.

## DISCUSSION

The distinction between CDC and UUC is critical for proper management but can represent a diagnostic challenge given the morphologic and immunohistochemical overlapping features between the 2 lesions. Both UUC and CDC are highly infiltrative carcinomas that induce strong desmoplastic host reaction and involve the renal medullary region occasionally colonizing preexisting collecting ducts. Furthermore, UUC may show foci of tubular differentiation whereas CDC can display occasional areas of urothelial-like morphology. Prior studies, addressed the use of immunohistochemical stains in resolving the differential diagnosis of CDC versus UUC in a high-grade renal sinus carcinoma.<sup>8,14</sup> The WHO criteria list HMWCK and *Ulex europeaus1* positivity as supportive evidence of CDC diagnosis. However, more recent studies illustrated the nonspecificity of these markers<sup>9</sup> emphasizing the need to explore the role of additional markers in such setting.

PAX genes are regulators of tissue development and cellular differentiation, acting to promote cell survival, cell migration, and lineage specification. PAX8 is one member of the PAX gene family of transcription factors that is crucial for lineage commitment in thyroid, Mullerian duct, and metanephron.<sup>10</sup> PAX8 is faithfully expressed by normal collecting ducts and differentiating nephrons.<sup>13</sup>

This study is the first to report on the expression of PAX8 in a large series of CDC. As expected, all 21 analyzed CDCs expressed PAX8 whereas 91% of examined UUC were negative for the marker (100% sensitivity and 93.9% specificity). In a separate study (results not shown),<sup>1</sup> we have recently expanded our evaluation of PAX8 expression in urothelial neoplasms and found 95% of over 200 examined tumors to be negative for the marker regardless of stage. PAX8 expression was also lacking in normal urothelium of the renal pelvis. Our finding of lack of PAX8 expression in UUC is in agreement with the recent study by Tong et al<sup>16</sup> who also showed absence of PAX8 expression in 76% of their 17 UUC tumors. Kobayashi et al<sup>9</sup> doubted a role for immunohistochemical analysis in the differential diagnosis of CDC and UUC citing probable histologic continuity and similarities between the renal pelvic urothelium and its transition to collecting duct epithelia. Specifically, Kobayashi et al documented the lack of utility of *Ulex europaeus* and HMWCK in this setting having found the former to be expressed universally by both CDC and UUC whereas the latter was positive in all tested UUC but also positive in almost one third of tested CDC. Our finding of universal PAX8 expression in CDC and its lack of expression in most UUC argues against the previously suggested common embryologic origin for the 2 types of neoplasms. PAX8 expression is largely limited to the urethric bud lineage-related tissue of mesodermal origin from which the collecting system develops from. The urothelium, in contrast, arises from the urogenital sinus of endodermal origin.<sup>2</sup> In this regard, our PAX8 inverse profile between CDC and UUC is in keeping with different embryologic origins for these 2 types of tumors and thus may support a non-urothelial lineage for CDC.

The diagnostic utility of p63 expression in urothelial carcinoma of the bladder is well established.<sup>6</sup> Likewise, p63 expression has been previously documented in majority of UUC.<sup>11</sup> Our p63 findings in UUC are in agreement with these prior studies.

Using each marker individually achieved a very high sensitivity for CDC (PAX8: 100%) and UUC (p63: 97%) but a less than optimal specificity. In contrast, using the 2 markers in combination in a given unknown tumor increased the specificity of achieving the correct diagnosis to 100% resulting in a positive predictive value of 1.0. However, this gain in specificity was on the account of a decrease in the sensitivity of PAX8 alone from 100% to 85.7% in CDC and the sensitivity of p63 alone from 97% to 88.2% in UUC. The distinction between CDC and UUC was not possible based on immunohistochemistry alone only in the rare scenario of PAX8+/p63+ profile. The latter profile occurred only in 6 of 55 (11%) cases.

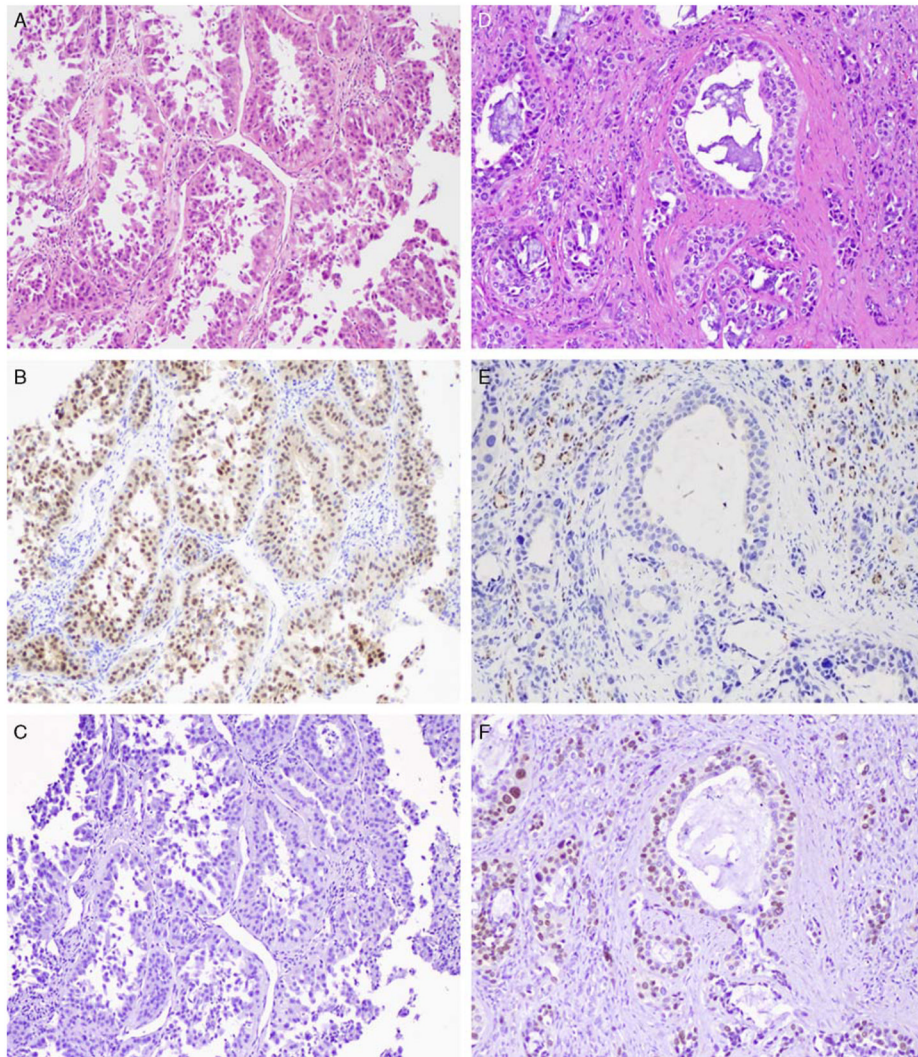
Needle biopsy technique is increasingly used in the diagnosis of renal masses identified on imaging modalities. Achieving the correct preoperative diagnosis is crucial in tumors that are amenable to nephron sparing surgery or ablation.<sup>7</sup> Our finding of a strong correlation of PAX8 and p63 expressions between TMA sections (spot sampling) and routine sections is reassuring and support the potential reliability of the PAX8/p63 use on needle biopsies for diagnostic purposes. Validation of our current findings in a needle-biopsy cohort of CDC and UUC would further confirm such utilization. The role of PAX8/p63 combination in differentiating CDC from renal tumors other than UUC (eg, renal medullary carcinoma) needs to be explored.

In summary, the combined use of PAX8 and p63 markers can reliably distinguish CDC from UUC tumors. A profile of PAX8+/p63- strongly favors a diagnosis of CDC, whereas a profile of PAX8-/p63+ favors UUC.

## References

1. Albadine R, Schultz L, Fajardo DA, et al. PAX8 expression in urothelial neoplasia—an immunohistochemical study of 236 cases. *Mod Pathol*. 2010; 23:174A.
2. Cuckow PM, Nyirady P, Winyard PJ. Normal and abnormal development of the urogenital tract. *Prenat Diagn*. 2001; 21:908–916. [PubMed: 11746143]
3. Eble, JN.; Sauter, G.; Epstein, JI., et al. Pathology and genetics of tumours of the urinary system and male genital organs. In: Srigley, JR.; Moch, H., editors. WHO Classification of Tumours. Vol. 2004. IARC Press; Lyon: 2004. p. 33-34.
4. Fedor HL, De Marzo AM. Practical methods for tissue microarray construction. *Methods Mol Med*. 2005; 103:89–101. [PubMed: 15542899]
5. Gupta R, Paner GP, Amin MB. Neoplasms of the upper urinary tract: a review with focus on urothelial carcinoma of the pelvicalyceal system and aspects related to its diagnosis and reporting. *Adv Anat Pathol*. 2008; 15:127–139. [PubMed: 18434765]
6. Higgins JP, Kaygusuz G, Wang L, et al. Placental S100 (S100P) and GATA3: markers for transitional epithelium and urothelial carcinoma discovered by complementary DNA microarray. *Am J Surg Pathol*. 2007; 31:673–680. [PubMed: 17460449]
7. Janzen N, Zisman A, Pantuck AJ, et al. Minimally invasive ablative approaches in the treatment of renal cell carcinoma. *Curr Urol Rep*. 2002; 3:13–20. [PubMed: 12084214]
8. Kafe H, Verbavatz JM, Cochand-Priollet B, et al. Collecting duct carcinoma: an entity to be redefined? *Virchows Arch*. 2004; 445:637–640. [PubMed: 15480763]
9. Kobayashi N, Matsuzaki O, Shirai S, et al. Collecting duct carcinoma of the kidney: an immunohistochemical evaluation of the use of antibodies for differential diagnosis. *Hum Pathol*. 2008; 39:1350–1359. [PubMed: 18602672]
10. Lang D, Powell SK, Plummer RS, et al. PAX genes: roles in development, pathophysiology, and cancer. *Biochem Pharmacol*. 2007; 73:1–14. [PubMed: 16904651]
11. Langner C, Ratschek M, Tsybrovskyy O, et al. P63 immunoreactivity distinguishes upper urinary tract transitional-cell carcinoma and renal-cell carcinoma even in poorly differentiated tumors. *J Histochem Cytochem*. 2003; 51:1097–1099. [PubMed: 12871991]
12. Lopez-Beltran A, Scarpelli M, Montironi R, et al. 2004 WHO classification of the renal tumors of the adults. *Eur Urol*. 2006; 49:798–805. [PubMed: 16442207]
13. Narlis M, Grote D, Gaitan Y, et al. Pax2 and pax8 regulate branching morphogenesis and nephron differentiation in the developing kidney. *J Am Soc Nephrol*. 2007; 18:1121–1129. [PubMed: 17314325]
14. Orsola A, Trias I, Raventos CX, et al. Renal collecting (bellini) duct carcinoma displays similar characteristics to upper tract urothelial cell carcinoma. *Urology*. 2005; 65:49–54. [PubMed: 15667862]
15. Srigley JR, Eble JN. Collecting duct carcinoma of kidney. *Semin Diagn Pathol*. 1998; 15:54–67. [PubMed: 9503506]
16. Tong GX, Yu WM, Beaubier NT, et al. Expression of PAX8 in normal and neoplastic renal tissues: an immunohistochemical study. *Mod Pathol*. 2009; 22:1218–1227. [PubMed: 19525927]





**FIGURE 1.**

A, Collecting duct carcinoma (hematoxylin and eosin stain). B, Diffuse 3+ positive nuclear immunohistochemical expression of PAX8. C, Negative staining for p63. (100 × magnification). D, Invasive high-grade urothelial carcinoma of renal pelvis (hematoxylin and eosin stain). E, Negative staining for PAX8 in UUC tumor; positive reactivity for PAX8 in background non-neoplastic renal tubules. F, Diffuse 3+ positive nuclear immunohistochemical expression of p63 in invasive urothelial carcinoma. Positive p63 is also seen in urothelial carcinoma colonizing preexisting collecting ducts.

**TABLE 1**

Immunohistochemical Expression of p63 and PAX8 in CDC and UUC

	n (%)	
	CDC	UUC
p63	3/21 (14.3)	33/34 (97)
PAX8	21/21 (100)	3/34 (8.8)

CDC indicates collecting duct carcinoma; UUC, upper tract urothelial carcinoma.



**TABLE 2**

Sensitivity, Specificity, and PPV of PAX8, p63, PAX8/p63 Immunostaining in the Diagnosis of CDC and UUC

	<b>Sensitivity (%)</b>	<b>Specificity (%)</b>	<b>PPV</b>
PAX8+ for CDC	100	91.2	0.87
PAX8+/p63- for CDC	85.7	100	1.0
P63+ for UUC	97	85.7	0.92
PAX8-/p63+ for UUC	88.2	100	1.0

CDC indicates collecting duct carcinoma; PPV, positive predictive value; UUC, upper tract urothelial carcinoma.