

## Oncology

## Bilateral renal involvement by solitary fibrous tumor – Report of a case in the post-WHO/2016 era



Edson S. Bezerra <sup>a, b, c</sup>, Oswaldo Pio Andrighetto <sup>c</sup>, Marcus V.S. Costa <sup>a, b</sup>,  
Leandro O. Chiarelli <sup>a, b</sup>, Willian Moleiro <sup>d</sup>, Luciana Schultz <sup>d, \*</sup>

<sup>a</sup> Faculdade de Medicina São Leopoldo Mandic – Campinas, Rua João Lino, 914, CEP: 13450-033, Santa Barbara d'Oeste, SP, Brazil

<sup>b</sup> Hospital da Santa Casa de Santa Bárbara D'Oeste, Rua João Lino, 914, CEP: 13450-033, Santa Barbara d'Oeste, SP, Brazil

<sup>c</sup> Hospital Municipal Dr. Mário Gatti, Av. Prefeito Faria Lima, 340, CEP: 13036-902, Campinas, SP, Brazil

<sup>d</sup> Instituto de Anatomia Patológica, Rua General Câmara, 1136, 5º andar, CEP: 13450-029, Santa Barbara d'Oeste, SP, Brazil

## ARTICLE INFO

## Article history:

Received 17 October 2017

Accepted 6 December 2017

Available online 9 December 2017

## Keywords:

Solitary fibrous tumor

Hemangiopericytoma

NAB2-STAT6

Nomenclature

Bilateral renal tumor

Renal metastasis

## 1. Introduction

Solitary fibrous tumors (SFT) are uncommon neoplasms that typically arise from the pleura and have unpredictable behavior. Extrapleural SFTs are rare in the genitourinary tract, where they more often involve the kidney. Definition between primary or metastatic SFT is critical for patient management, impacting prognosis and treatment. SFTs share many similarities to hemangiopericytoma (HPC), but recent molecular improvements place most HPC as cellular variants of SFT. We describe the case of bilateral renal masses in a young male, exemplifying why such a shift in terminology is important, especially when molecular knowledge can be translated into accessible diagnostic tools.

In 1870 Wagner described a fibrous or reticular tumor

(“retikuliert tuberkel”) with malignant features involving the pleura. The term “solitary” was proposed later to differentiate from mesothelioma. SFT and HPC have since been separate entities by the WHO Classifications of several organs. However, over time, the vascular pattern characteristic of HPCs was found in 15% of all soft-tissue tumors, suggesting that this feature represents a histologic pattern instead of a clinicopathologic entity. Furthermore, recent research showed that these lesions share the chromosomal fusion<sup>1</sup> NAB2-STAT6, leading the following WHO editions to incorporate most HPC as part of the spectrum of SFT (Fig. 1).

## 2. Case presentation

A 39 year-old male complained of abdominal discomfort and enlargement of the right scrotum for 6 months, with no urinary symptoms or weight loss. Initial investigation at the community health facility diagnosed varicocele and indicated surgery. Palpation of the abdomen under anesthesia revealed a large mobile mass (left hypochondrium to iliac region) and a transcutaneous biopsy was preferred. Histology revealed a monotonous spindle cell proliferation, with bland nuclear features and low proliferation rate, in a collagenous background, with no necrosis and areas of CD34 immunoreexpression, suggestive of SFT. He then reported to us for a second opinion.

Aside from surgical excision of a meningioma 7 years ago, there was no relevant history. He had discrete anemia (hemoglobin: 11.7 mg/dL; hematocrit: 33%) and preserved renal function. Abdominal computed tomography (CT) revealed nodular heterogeneous confluent masses in the retroperitoneum, connected to the left kidney, and smaller similar lesions in the contralateral kidney (Fig. 2). Radical left nephrectomy was performed. There were no peritoneal implants or visible adenopathy.

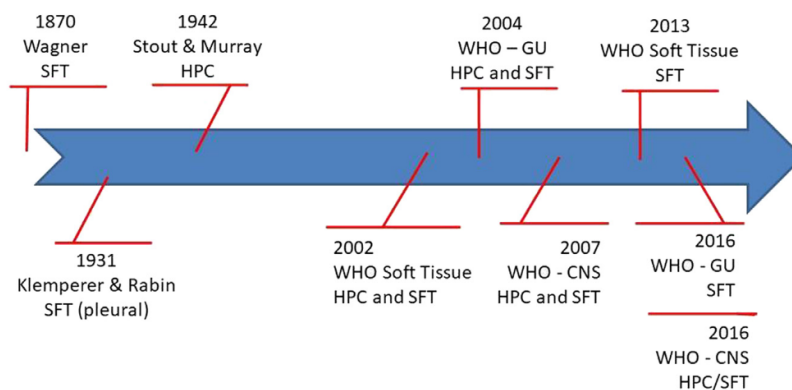
Gross evaluation (Fig. 2) evidenced an exophytic lesion invading the renal parenchyma and hilum. Histology (Fig. 3) showed variable cellularity of spindle to ovoid cells, in a haphazard arrangement. Cells lacked significant atypia and were separated by thin bands of collagenous stroma that produced areas of fibrous background.

\* Corresponding author.

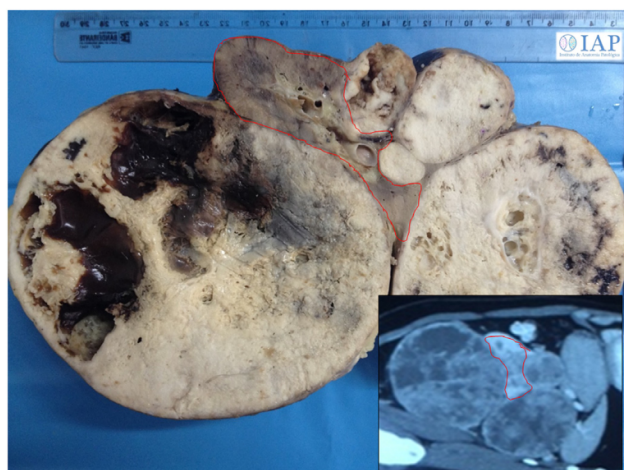
E-mail addresses: [edson.s.bezerra@gmail.com](mailto:edson.s.bezerra@gmail.com) (E.S. Bezerra), [oswaldoandrighetto@gmail.com](mailto:oswaldoandrighetto@gmail.com) (O.P. Andrighetto), [marcusvsc@outlook.com](mailto:marcusvsc@outlook.com) (M.V.S. Costa), [leandro.urologia@gmail.com](mailto:leandro.urologia@gmail.com) (L.O. Chiarelli), [wmmoleiro@gmail.com](mailto:wmmoleiro@gmail.com) (W. Moleiro), [lu\\_schultz@gmail.com](mailto:lu_schultz@gmail.com) (L. Schultz).

<https://doi.org/10.1016/j.eucr.2017.12.003>

2214-4420/© 2017 The Authors. Published by Elsevier Inc. This is an open access article under the CC BY-NC-ND license (<http://creativecommons.org/licenses/by-nc-nd/4.0/>).



**Fig. 1.** Terminology evolution of solitary fibrous tumors (SFT) and hemangiopericytomas (HPC). Pleural fibrous tumor (FT) was described in 1870 and later the term solitary was added to differentiate from mesothelioma. HPCs are thought to derive from pericytes, but show significant clinical and morphological overlap with SFT, which are fibroblastic proliferations. They had been considered distinct entities by the WHO Classifications until a shared chromosomal fusion was described, leading to incorporate most HPC as part of the SFT spectrum. Because meningeal HPC show higher rates of metastasis than classic SFT, the CNS edition opted for a composite terminology (HPC/SFT). WHO: World Health Organization; CNS: central nervous system. \* Wagner E. *Arch Heilk.* 1870; 11:497. † Klemperer & Rabin. *Arch Pathol.* 1931;11:385-412. ‡ Stout & Murray. *Ann Surg.* 1942 Jul. 116(1):26-33.



**Fig. 2.** Anatomy of left kidney lesion. Grossly, the tumor was predominantly exophytic with invasion of renal parenchyma and hilum. Residual kidney is highlighted in red. Inset: correlation with coronal CT view. (For interpretation of the references to colour in this figure legend, the reader is referred to the Web version of this article.)

Hemangiopericytoma-like vasculature and ectatic vessels were prominent. Despite cystic degeneration, necrosis was absent. Mitotic index was 3.8/10HPF. Immunohistochemistry was diffusely positive for CD99 and BCL2, and focally positive for CD34. The lesion also showed nuclear expression of STAT6 - a surrogate for NAB2-STAT6 fusion. Cytokeratins, WT1, FLI-1, SMA and S-100 were negative, ruling out sarcomatoid carcinoma, synovial sarcoma, Wilms tumor, rhabdomyosarcoma, leiomyosarcoma and melanoma. A diagnosis of fibroblastic lesion of low malignant potential in the HPC/SFT spectrum was made.

One month post-operatively, ultrasound revealed enlargement of the nodules in the remaining kidney. Given such rapid progression, a metastatic nature was suspected and the previous brain tumor was retrieved for pathology review. The meningeal lesion was similar to the renal tumor, with no classic meningothelial areas or psammomatous calcifications. The original work up was negative for CD34, with weak focal expression of EMA, but diffusely positivity for CD99 and BCL2. Although this profile, by itself, was more suggestive of meningioma, complementary techniques were

contributory. Silver stain revealed a reticulin-rich lesion, in a single-cell pattern of distribution and STAT6 was diffusely positive, providing confidence for contemporarily reclassifying the lesion as meningeal SFT.

The final diagnosis was a meningeal SFT with bilateral renal metastasis. The patient was submitted to chemotherapy with Taxol and developed febrile neutropenia. At one year follow-up he was stable, with Creatinin levels within the normal range (0.7 mg/dL) but CT suggested possible liver and pancreas metastasis. He refused more aggressive chemotherapy (isophosphamide and doxorubicin) and lost follow-up. He reported 16 months later with clinically uncontrollable hematuria and a palpable mass from the right hypochondrium to the iliac region. A right radical nephrectomy was performed and other metastasis were not confirmed. He is currently under permanent dialysis.

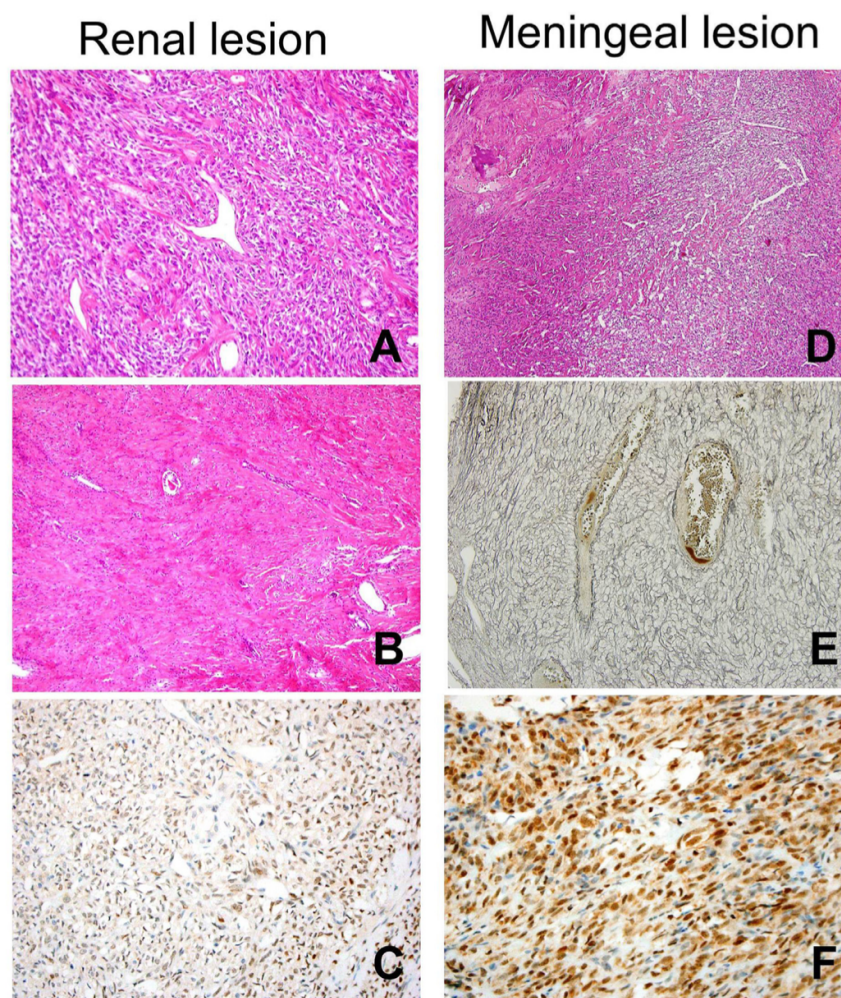
### 3. Discussion

Clinical presentation of renal SFT is non-specific: pain can present on larger masses and hematuria may indicate invasion of the pyelocalical system. While the lung is the most frequent metastatic site of primary renal SFT, the kidneys have been reported as a frequent metastatic site for meningeal HPC/SFT. Except for few isolated reports, data is imprecise with regards to how often SFT metastasizes to the parenchyma or retroperitoneal adipose tissue. We believe parenchymal invasion should raise the possibility of a metastatic nature.

Most tumors are indolent, whereas aggressive behavior has been reported in histologically benign appearing lesions, therefore grading schemes are imprecise. While a uniform nomenclature allows for observation of larger series, some argue that the name HPC carries prognostic information by itself. At least in the meninges, former-HPCs have higher metastatic potential than classic SFTs, frequently as late recurrences, like our case. We found three previous reports of meningeal HPC with bilateral renal metastasis<sup>2-4</sup>: all males between 37 and 58 years old, progressing after 10–14 years of primary excision.

The fibroblastic variant of meningioma is particularly important in the differential of HPC/SFT and histological identification of typical meningothelial areas and calcified psammoma bodies aid distinction. Reticulin stain and STAT6 immunohistochemistry were helpful in our experience. Retroperitoneal dedifferentiated





**Fig. 3.** Histology of SFT, O.M., 40x. Renal lesion consisted of a proliferation of bland spindled to ovoid cells, with hemangiopericytoma-like vasculature (A) in a variably collagenous stroma that produced areas of frank fibrous background (B) and positivity for STAT6 (C). Review of previous meningeal lesion showed similar morphology (D), a single-cell pattern of reticulin histochemistry (E) and diffuse nuclear positivity for STAT6 (F).

liposarcomas should be in the differential of “fat containing” SFTs since they may show STAT6 positivity.<sup>5</sup> Sarcomatoid renal cell carcinoma should also be excluded, since most extrapleural SFTs express PAX8.

#### 4. Conclusion

Advanced and bilateral renal SFTs should prompt investigation of extra-renal primary sites. The NAB2-STAT6 fusion has been shown to be specific for SFTs, encouraging the possibility of targeted therapy. STAT6 expression is a surrogate marker that enhances contemporary diagnostic accuracy.

#### Consent

This research did not receive any specific grant from funding agencies in the public, commercial, or not-for-profit sectors.

#### Conflicts of interest

All the authors declare no conflict of interest regarding this

scientific communication.

#### Appendix A. Supplementary data

Supplementary data related to this article can be found at <https://doi.org/10.1016/j.eucr.2017.12.003>.

#### References

- Chmielecki Juliann, Crago3 Aimee M, Rosenberg Mara, et al. Whole exome sequencing identifies a recurrent NAB2-STAT6 fusion in solitary fibrous tumors. *Nat Genet.* 2013 February;45(2):131–132.
- Heppe RK, Donohue RE, Clark JE. Bilateral renal hemangiopericytoma. *Urology.* 1991;38:249–253.
- Alleemudder A, Pillai J. Bilateral renal involvement from a primary brain tumor. *World J Nephrol Urol.* 2016;5(1):23–25.
- Hammontree LN, Whitehead K, Markert JM. Bilateral metastatic renal hemangiopericytoma ten years after primary intracranial lesion. *Int Braz J Urol.* 2006;32(3):306–307.
- Ullman D, Gordetsky J, Siegal GP, Prieto-Granada CN, Wei S, Stevens TM. PAX8 expression in solitary fibrous tumor: a potential diagnostic pitfall. *Appl Immunohistochem Mol Morphol.* 2017 Jul 26. <https://doi.org/10.1097/PAI.0000000000000561>.

